

## **ORAL MELANOMA**

### **Definition**

Melanoma is a highly malignant neoplasia, arising from melanocytes, the cells that produce the brownish pigment melanin. Melanin is the determinant in skin colour and protects against ultraviolet (UV)-A and UV-B irradiation from the sun. As most fair-skin individuals grow older, melanocytes often proliferate, forming concentrated clusters that appear on the surface as small, dark, macular or nodular spots, which are usually harmless. When cell proliferation occurs in a controlled and contained manner, the resulting lesion is benign and termed *naevus*. Sometimes, melanocytes grow out of control, producing irregularly pigmented, asymmetrical and poorly demarcated lesions, suggesting that malignant transformation has occurred, in the form of a life-threatening disease called *melanoma*. Sometimes, melanoma manifests suddenly as a rapidly growing mass without any preceding naevus.

### **Epidemiology**

The most common sites for mucosal melanomas are the head and neck region, followed by anal/rectal region, female genital tract, and urinary tract. Primary malignant melanomas of the oral squamous mucosa are rare, accounting for approximately 0.3-2% of all malignant melanomas, about 4% of head and neck melanomas and 0.5% of all oral malignancies. The low prevalence of primary oral melanoma is in contrast to cutaneous melanoma which has been increasing by 4–6% per year since 1973, with 41,600 new cases diagnosed and 7200 melanoma-related deaths in 1998 in the US.

Patients affected by oral melanomas are typically older and a decade earlier in males than in females. Melanomas may be found more frequently in men, with a male-to-female ratio of almost 2:1, but gender distribution varies, depending on geographic location. Mucosal melanomas are relatively common in Japan, with the oral cavity being the most frequent site, whereas, melanoma of the skin is less common in Japanese than in Caucasians.

### **Clinical Presentation**

Oral melanoma may present either as a rapidly-developing pigmented lesion or as a tumour preceded by a pigmented area for a variable period of time. Lesions may be single or multiple, macular or nodular, with variable colour and shape, and can be either primary or metastatic. Associated symptoms which are not specific for melanoma but are shared by a number of other primary tumours of the oral cavity

include ill-fitting dentures, loose teeth, bone loss, bleeding and mucosal ulceration. Oral melanoma may equally arise from neoplastic transformation of either melanocytes or naevus cells although intra-oral nevi are uncommon and their malignant transformation is less substantiated than their skin counterparts. Intra-oral nevi are often seen on the hard palate and less frequently in the buccal and labial mucosa, gingiva and alveolar ridge, and may present as small, flat or elevated macules or papules, that may also be non-pigmented. Similarly, oral melanomas have also a decided predilection for the palate, followed by the maxillary gingiva. Non-pigmented forms of malignant melanoma often present as soft, vascular tumours, that cannot be distinguished clinically from other benign or malignant oral tumours and in such cases the histopathological examination is essential to establish a definitive diagnosis.

### **Aetiopathogenesis**

The key to understanding the process by which melanocytes are transformed into malignant melanoma seems to lie in the interplay between genetic factors and the UV spectrum of sunlight, although the nature of this relation has remained obscure. Recently, prospects for elucidating the molecular mechanisms underlying such gene-environment interactions have brightened considerably through the development of UV-responsive experimental animal models of melanoma. Genetic factors remain as the likely causative agent for oral melanomas. In fact, it has been demonstrated that point mutations in P53 tumour suppressor gene may be associated with mucosal melanomas. Nonetheless, probably, one of the major reasons for the lack of understanding regarding mucosal melanomas is the rarity of this malignancy. This contributes to difficulties in searching a sufficient number of cases to evaluate on a scientific and standardised manner, and its aetiology thus remains unclear.

### **Diagnosis**

When an oral melanoma is encountered, it is important to exclude the possibility of malignant melanotic lesions elsewhere in the body. Differential diagnosis should include oral melanotic macule, naevus, amalgam tattoo, Kaposi's sarcoma, smoking-associated melanosis, post-inflammatory pigmentation and melanoacanthoma. Suspicious irregular or heterogenous macules occurring in high risk sites such as the palate and gingiva, should be biopsied as soon as possible. Excisional biopsy can be carried out on lesions of small size, while, incisional biopsy is preferable for lesions that are large and should be performed in the thickest or the darkest area of the lesion, since light areas suggest regression; multiple biopsies should be considered

from heterogenous lesions.

The histologic diagnosis of oral melanoma is easy when the individual tumour cells are found to be melanin-rich, but amelanotic lesions may resemble other neoplasms due largely to the ability of melanoma to adopt a deceptively wide variety of architectural and cytologic patterns. Therefore, the diagnosis is best confirmed by immunohistochemical studies. Stains that have been employed most commonly for the diagnosis of melanoma include S-100, HMB-45, HLA-DR, PCNA and Melan-A, a melanoma-specific marker. It should also be noted that the histologic classification of oral melanoma does not fit well into the categories of the cutaneous counterpart.

### **Treatment**

Due to the rarity of oral melanoma, treatment protocols are scarce and most of the information accrued has been drawn from retrospective review articles. Surgical excision remains the mainstay of treatment and adequate resection may involve approximately a centimetre margin all around the primary tumour, with or without neck dissection. However, anatomical complexities within the region can hamper attempts at complete excision. The presence of regional disease is uncommon and may not influence the therapeutic outcome as significantly as in the cutaneous counterpart. Therapeutic neck lymph node dissections are performed for patients with clinically palpable regional lymph nodes.

Malignant melanoma has been traditionally regarded as a radio-resistant tumour. However, radiation therapy as a primary modality is occasionally used for the elderly and medically compromised, while post-operatively is given as a fractionation regimen for the treatment of selected patients with advanced tumours or where tumour may be either multicentric or the margins may be very close. Preoperative chemotherapy is occasionally used to reduce the size of the melanoma and improve surgical management, while post-operatively, chemotherapy is mainly used in the treatment of disseminated disease and for palliation. Chemotherapeutic agents which are used include dimethyltriazeno imidazole carboxamide, solely or in combination with vincristine and dactinomycin. Immunotherapeutic drugs that are occasionally used include interferon-a, interleukin 2, cimetidine and intralesional lymphokines.

### **Prognosis-complications-prevention**

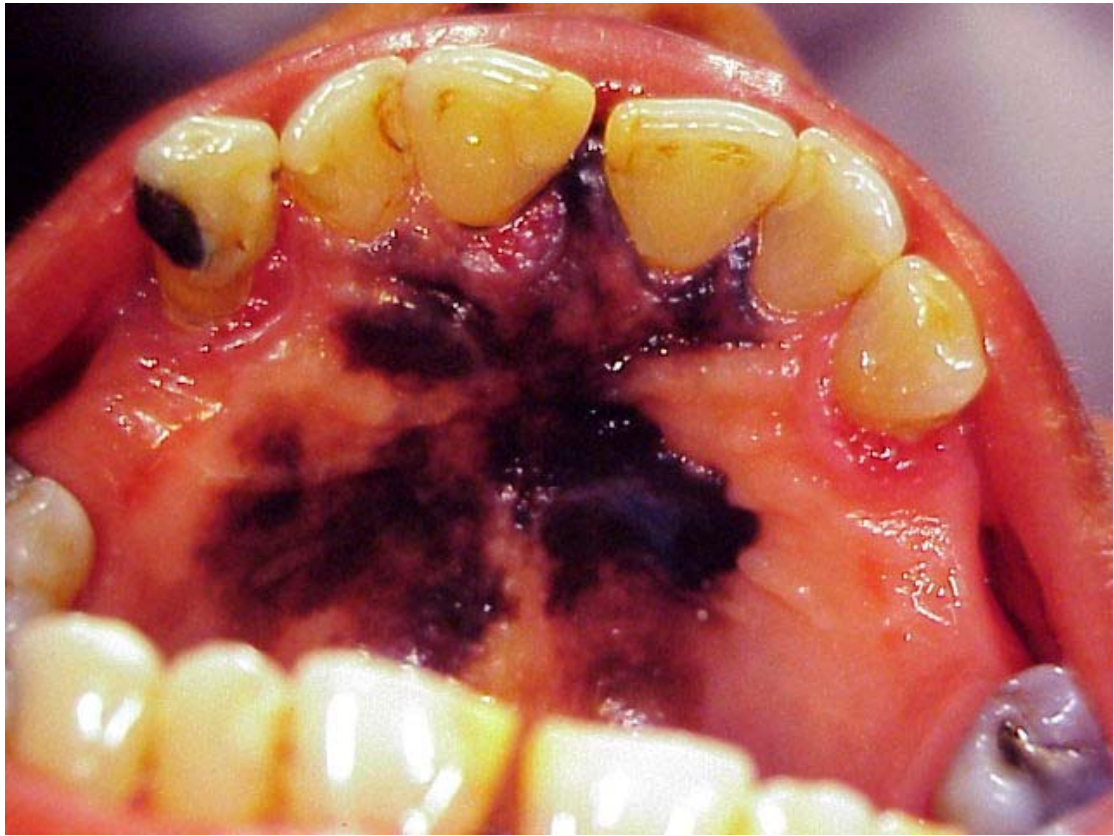
A system for categorising patients with oral melanoma is in operation and recognises three stages: Stage I, for localised disease, Stage II, when nodal metastases are present, and Stage III, when distant metastases are present. Of the patients with oral melanomas, 25% present with nodal involvement and 20% demonstrate clinical or

radiographic evidence of generalised dissemination, most commonly in lung and liver.

The prognosis for patients with oral melanoma remains discouragingly low (5-20%), much lower than that of patients with cutaneous melanoma, since many of these patients are diagnosed at a late stage.

The major factor determining outcome in patients with oral melanoma is the extent of the primary tumour, while tumour thickness greater than 4-5 mm, vascular invasion on light microscopy, and the development of distant metastases, either at presentation or in development during treatment, represent ominous findings, not compatible with prolonged survival. The prognostic value of regional lymph node involvement remains controversial, and whether or not, preexisting melanosis affects the clinical outcome of oral melanomas compared with melanomas presenting de novo is also doubtful.

Indeed, a history of pre-existing melanosis (as long as 10 years), can be found in about one third of all patients with oral melanoma, as the one encountered on the skin, representing the radial growth phase, before the lesion evolves into a vertical infiltrating lesion. Apart from this resemblance, the two entities seem to be biologically and histologically distinct. The oral environment is unique and the abundant blood supply of the oral cavity may facilitates blood vessel invasion and hematogenous dissemination early in the course of the disease. In fact, most commonly, clinical symptoms of oral melanoma are present when significant vertical invasion of the tumour cells into the underlying tissues, including the bone, has already occurred. Finally, early biopsy and close follow-up of any pigmented lesion in the oral cavity secures early diagnosis, simplifies treatment and greatly improves the prognosis.



**Figure 1.** Oral melanoma

### **Further reading**

- 1 Umeda M, Shimada K. Primary malignant melanoma of the oral cavity—its histological classification and treatment. *Br J Oral Maxillofac Surg* 1994; 32:39-47.
- 2 Barker BF, Carpenter WM, Daniels TE et al. Oral mucosal melanomas. *Oral Surg. Oral Med. Oral Pathol Oral Radiol Endod* 1997; 83:672-9.
- 3 Hicks MJ, Flaitz CM. Oral mucosal melanoma: Epidemiology and pathobiology. *Oral Oncol* 2000; 36:152-169.
- 4 Gu GM, Epstein JB, Morton TH. Intra-oral melanoma: Long-term follow-up and implication for the dental clinicians. A case report and literature review. *Oral Surg. Oral Med. Oral Pathol Oral Radiol Endod* 2003; 96:404-13.
- 5 Medina JE, Ferlito A, Pellitteri PK et al (). Current management of mucosal melanoma of the Head and Neck. *J. Surgical Oncology* 2003; 83:116-122.